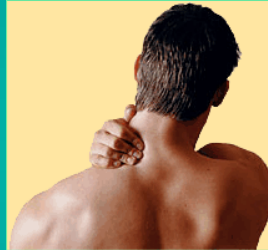

# Cervical Spine Injuries and Neck Pain



Pablo Vazquez-Seoane, M.D.

48th Annual Symposium on  
Sports Medicine

## Financial Disclosure

- Nothing to disclose

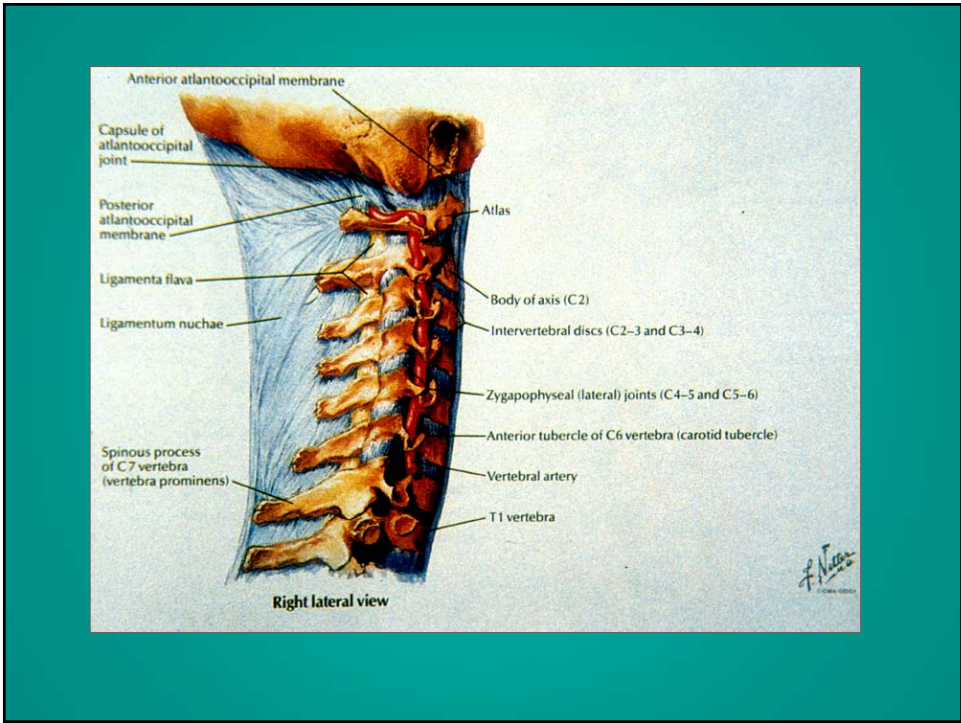
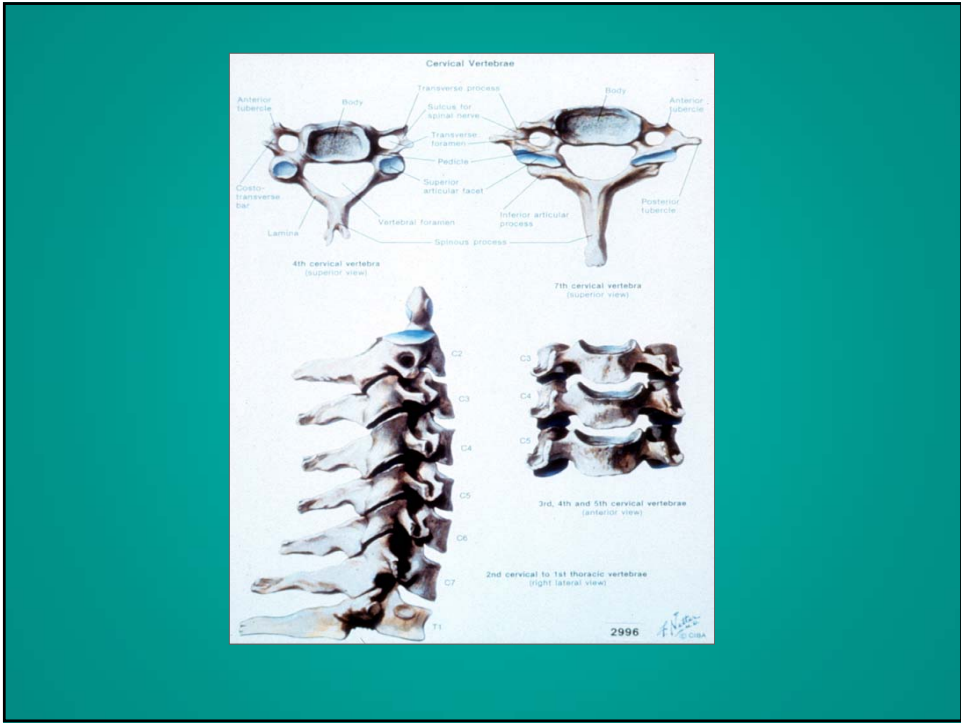This presentation is the intellectual property of the author.  
Contact them for permission to reprint and/or distribute.

# Cervical Spine Injuries and Neck Pain

- Common problem
- Potentially very serious
- Injuries may involve multiple structures:
  - Ligaments, disks, muscle, bone, facet joints, spinal cord, or nerve roots

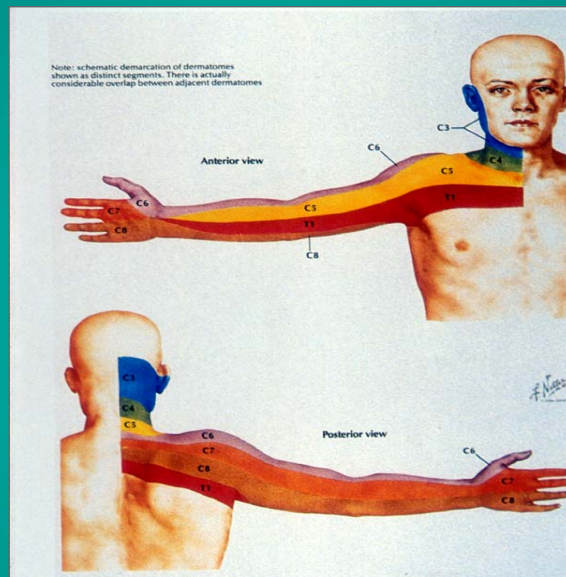
## Cervical Spine

### Anatomy



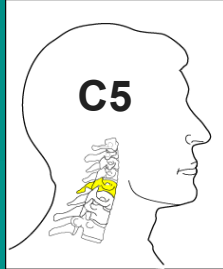
This presentation is the intellectual property of the author.  
 Contact them for permission to reprint and/or distribute.

# Physical Exam

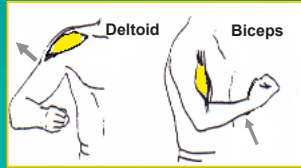


This presentation is the intellectual property of the author.  
Contact them for permission to reprint and/or distribute.

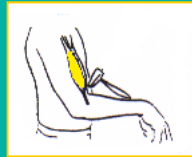## C5 Neurologic Level



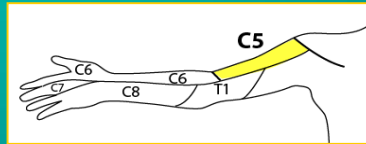
Motor



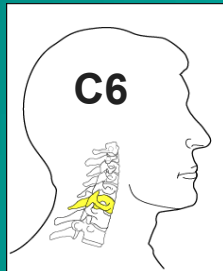
Reflex




Sensation



## C6 Neurologic Level



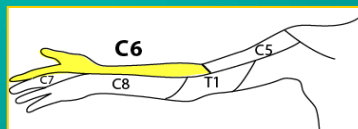
Motor



Reflex

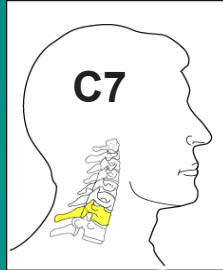


Sensation

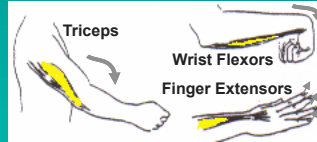


This presentation is the intellectual property of the author.  
Contact them for permission to reprint and/or distribute.

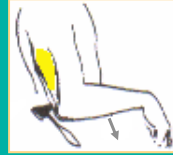## C7 Neurologic Level



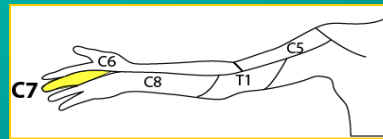
Motor



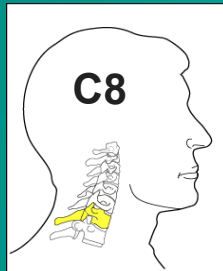
Reflex



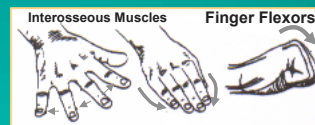
Sensation



## C8 Neurologic Level

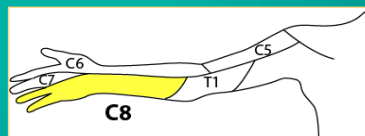


Motor

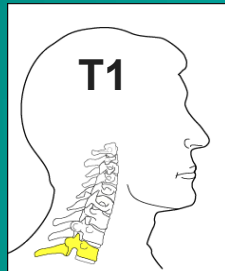


Reflex--None

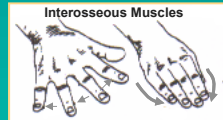
Sensation



## T1 Neurologic Level

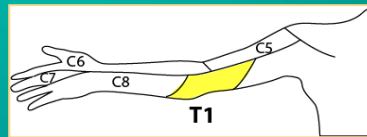


Motor



Reflex--None

Sensation




## Acute Injuries

Severe Injuries  
Fractures and Dislocations

This presentation is the intellectual property of the author.  
Contact them for permission to reprint and/or distribute.

# Cervical Spine Injuries Unconscious Patient

- Very serious problem
- Always assume a cervical spine injury
- Follow spine injury protocol with head and neck support, log roll, and back board



This presentation is the intellectual property of the author.  
Contact them for permission to reprint and/or distribute.



# Cervical Spine Injuries

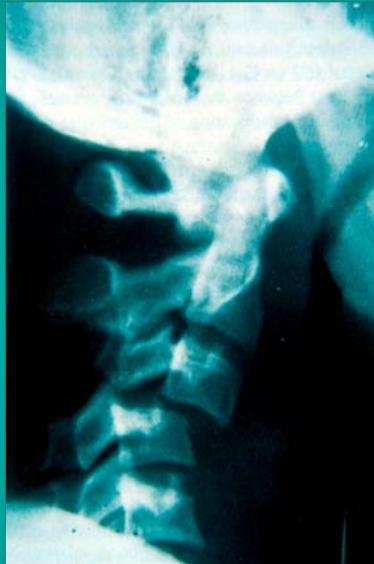
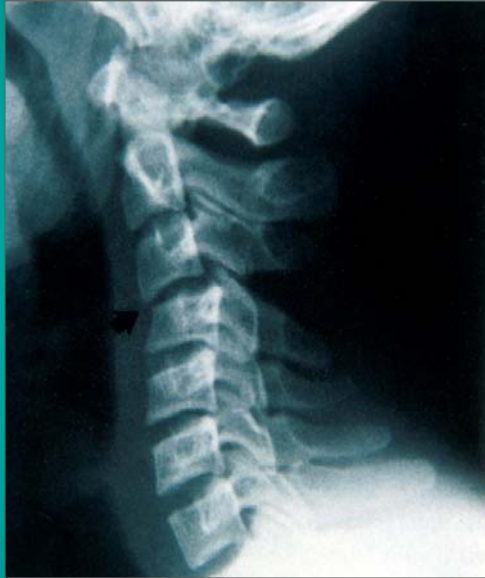## Mechanism of Injury

- Axial loading
- National Football Head and Neck Injury Registry
  - Formed in 1975
  - Data led to rule changes:
    - Banning spearing
    - No head first contact

# Cervical Spine Injuries

## Fractures and Dislocations

- Dislocations or subluxations:
  - Can be mild or severe
  - Involve serious ligament and soft tissue injuries with potential instability
  - Facet dislocations or jumped facets are very serious
  - Neurological risk, careful neurological exam
  - Many will need surgical treatment

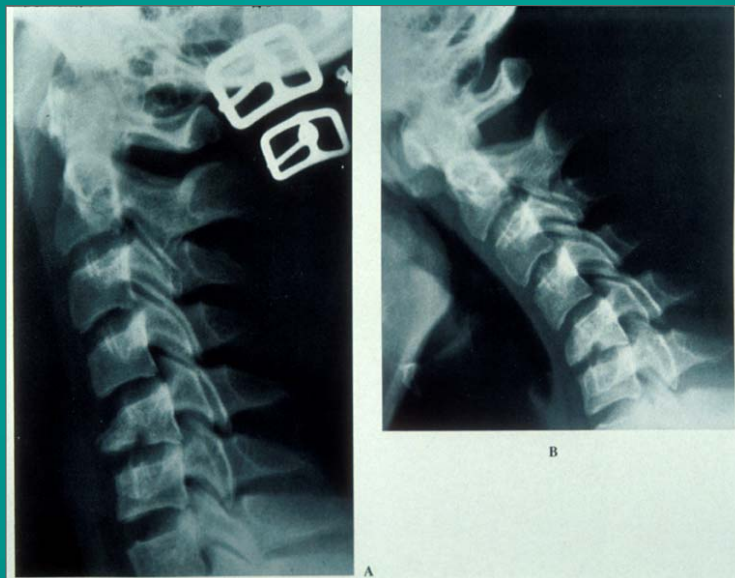


This presentation is the intellectual property of the author.  
Contact them for permission to reprint and/or distribute.

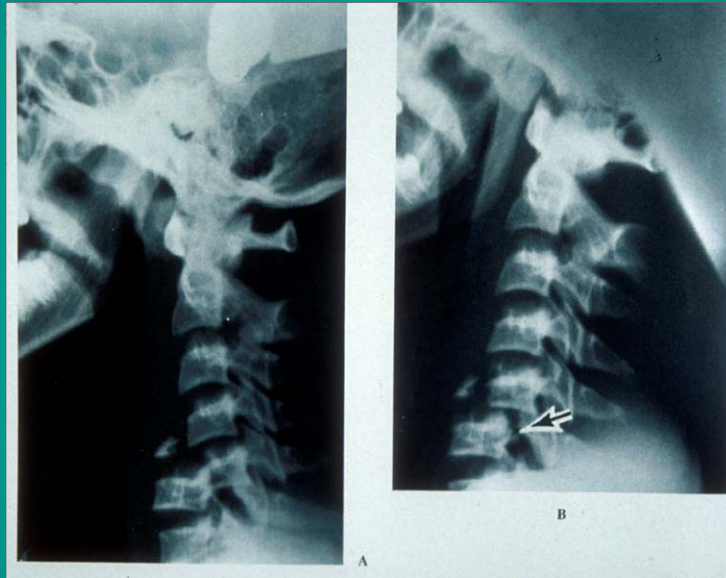
# Cervical Spine Injuries

## Fractures and Dislocations

- Fractures:
  - May involve vertebral body, lamina, facet joint, or spinous process
  - Can be mild or very severe
  - Fracture and dislocation combination usually is the worst case scenario
  - Neurological risk, careful neurological exam
  - Many may need surgical treatment



This presentation is the intellectual property of the author.  
Contact them for permission to reprint and/or distribute.



## General Types of Injuries

### Cervical Sprain

- Common injury
- Ligament, muscle, soft tissue injury
- Localized neck pain, stiffness
- No numbness or weakness
- Treatment: rest, medications: muscle relaxants, anti-inflammatories
- Treatment: rehab
- Return to play: normal ROM

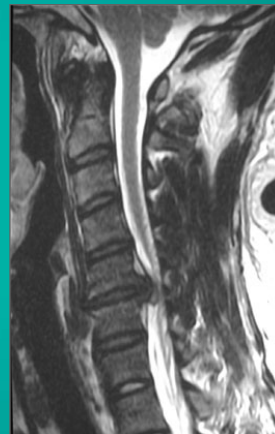
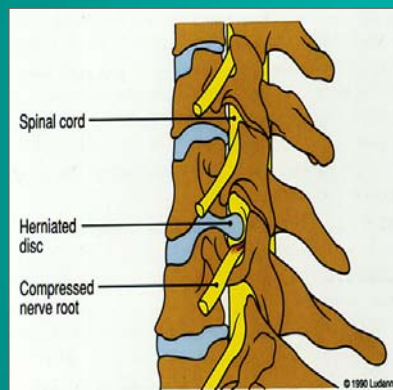
This presentation is the intellectual property of the author.  
Contact them for permission to reprint and/or distribute.

# General Types of Injuries

## Cervical Disk Injuries

- May include tears or herniations
- Radicular pain and/or numbness, weakness
- Persistent symptoms
- Treatment varies, depends on severity: rehab, medications, injections, or surgery

## Cervical HNP



This presentation is the intellectual property of the author.  
Contact them for permission to reprint and/or distribute.

## Nerve Root/Brachial Plexus Neuropraxia

- Burner or stinger
- Temporary arm numbness, weakness
- Stretch injury
- Usually involving C6
- Return to play only when symptoms are COMPLETELY resolved
- Best prevention is in good shoulder pads

## General Types of Injuries Cervical Cord Neuropraxia

- Rare severe condition
- Symptoms usually bilateral or involving the lower extremities, transient quadriplegia
- On severe cases may last over one week
- Needs evaluation with MRI and frequent neurological examinations
- Treatment based on severity and MRI findings

Thank you!

This presentation is the intellectual property of the author.  
Contact them for permission to reprint and/or distribute.